



ราชวิทยาลัย  
จุฬารัตน์

# THE ELECTROCARDIOGRAPHY: TRACING CASES ANALYSIS

The electrocardiography ; tracing cases

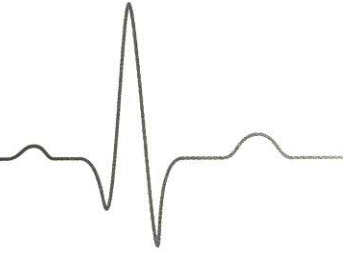
WG140 ๙915 2565 ๙.1



Barcode \*10053607\*


ห้องสมุดวิทยาลัยพยาบาลบรมราชชนนี สุรินทร์

# สารบัญ



- 3** • บทนำ
- 7** • ECG No 01 STEMI: infero-posterior wall
- 13** • ECG No 02 STEMI: inferior wall and right ventricular infarction
- 15** • ECG No 03 STEMI: sudden cardiac arrest during coronary intervention
- 21** • ECG No 04 STEMI: extensive anterior wall with cardiogenic shock
- 24** • ECG No 05 Regular narrow complex tachycardia
- 29** • ECG No 06 Irregular wide complex tachycardia after adenosine injection
- 33** • ECG No 07 Multifocal atrial tachycardia
- 37** • ECG No 08 Fascicular ventricular tachycardia
- 41** • ECG No 09 AV dissociation in regular wide complex tachycardia
- 44** • ECG No 10 Repetitive monomorphic non-sustained RVOT-VT
- 49** • ECG No 11 Bidirectional ventricular tachycardia
- 55** • ECG No 12 Sick sinus syndrome: Escape-Echo VS Escape-Capture beats





- 60 • ECG No 13 Electrical alternan
- 64 • ECG No 14 Hypokalaemic periodic paralysis
- 68 • ECG No 15 Mitral stenosis and pregnancy
- 73 • ECG No 16 Anterior wall STEMI VS Left ventricular aneurysm
- 77 • ECG No 17 Incessant atrial tachycardia induced cardiomyopathy
- 84 • ECG No 18 Right focal atrial tachyarrhythmia ablation
- 91 • ECG No 19 Acute pericarditis VS STEMI VS Early repolarization
- 98 • ECG No 20 Acute chest pain: pulmonary embolism
- 105 • ECG No 21 Hyperkalemia: isorhythmic atrioventricular dissociation
- 114 • ECG No 22 Wolff-Parkinson-White Syndrome
- 119 • ECG No 23 Pace malfunction: failure to capture
- 125 • ECG No 24 Syncope & trifascicular block: a misnomer
- 131 • ภาคผนวก 1. ทบทวนการอ่านคลื่นไฟฟ้าหัวใจ  
2. Wide QRS complex tachycardia
- 155 • รายงานอายุรแพทย์โรคหัวใจและหลอดเลือดผู้ร่วมนิพนธ์ต้นฉบับ